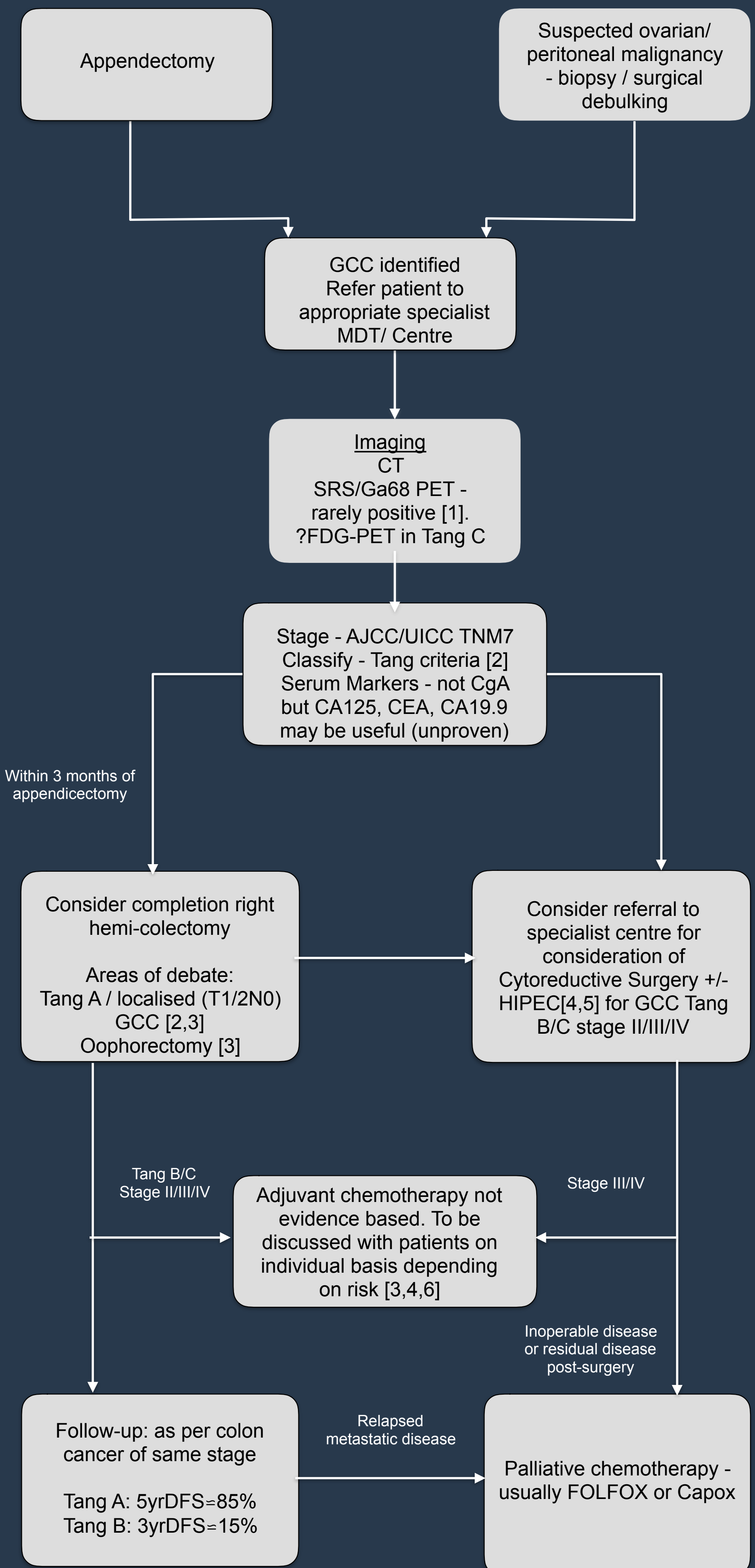


# UKINETS bitesize guidance

## Goblet Cell Carcinoma

### PAGE 1 - MANAGEMENT ALGORITHM



# UKINETS bitesize guidance

## Goblet Cell Carcinoma

### PAGE 2 - NOTES

Goblet cell carcinoma (GCC) of the appendix are very rare epithelial neoplasms with malignant behaviour: incidence 0.01-0.05/100 000 population/year.

Goblet cell carcinoma of the appendix should be considered as a completely different entity, pathologically and prognostically, to pure neuroendocrine tumours of the appendix.

Two thirds of cases are incidental findings after appendicectomy or ileo-caecal resection for abdominal pain and right iliac fossa mass.

Metastasis found at presentation (most commonly to peritoneum, omentum, ovaries, liver) in approximately 10% of tumours.

Consideration should be given to refer all patients diagnosed with GCC to a specialist centre (NET/Colorectal) for MDT review of diagnosis and treatment plan development.

#### Diagnostic workup:

CT scan of the thorax, abdomen and pelvis to look for metastasis. Alternatively, MRI of abdomen and pelvis can be performed.

Somatostatin receptor imaging (SRI) is very rarely positive and should not be done routinely. FDG PET may be useful in detecting disseminated disease in high grade tumours.

Tumour markers; CEA, CA 19-9 and CA 125 are more likely to be positive than neuroendocrine markers. Routine measurement of chromogranin A is not recommended.

Pathological review: use of Tang criteria[2] may help in prognostication regarding relapse and survival. This is part of RCPATH appendiceal neuroendocrine tumour dataset. Review by specialist GI or neuroendocrine histopathologist is recommended.

Staging according to UICC/AJCC as for adenocarcinoma of the appendix.

#### Treatment:

Localised disease;

After appendicectomy recommendations are that a completion right hemicolectomy (within 3 months of initial surgery) should be considered. However, good evidence is lacking as to the benefits of this in terms of relapse free and overall survival, particularly in small (T1/2 N0) and low grade (Tang A) tumours. Such an approach needs to be individualised and discussed with patients.

In view of risk of peritoneal spread to ovaries it has been suggested that prophylactic bilateral salpingo-oophorectomy may be beneficial to improve relapse free survival. Good evidence is lacking for this and it needs to be discussed with patients on a case by case basis.

Cytoreductive surgery +/- hyperthermic intra-peritoneal chemotherapy (HIPEC) should also be considered on an individual patient basis<sup>[4,5]</sup>. Referral to national peritoneal cancer services ( Manchester / Basingstoke ) for MDT review or advice. Patients who may benefit the most are incompletely resected GCC with stage II/III/IV<sup>[4]</sup>.

Chemotherapy;

Adjuvant chemotherapy – not evidence based but can be considered in cases with high risk of relapse, e.g. GCC Tang B/C and/or stage II/III/IV also following cytoreductive surgery +/- HIPEC is stage III/IV <sup>[3,4,6]</sup>. 5-fluorouracil + oxaliplatin based chemotherapy regimen is commonly used.

Palliative chemotherapy: A 5-fluorouracil based chemotherapy combination is recommended. FOLFIRI (+/- cetuximab) as per colorectal regimens.

#### Follow up:

Median overall survival varies depending on stage and grade (trend to significance of Tang classification on multivariate analysis in a number of series) – e.g. 25 months in patients presenting with peritoneal disease, 43 – 83 months in retrospective single centre case series of mixed populations <sup>[3,4]</sup>.

In patients fit enough for further intervention appropriate clinical, biochemical and imaging follow up ( depending on stage and grade ) should be performed. This may be most appropriate via colorectal MDT as per equivalent colorectal adenocarcinoma protocol. However, follow up should be considered for a longer period as significant risk of relapse remains after 5 years.



UK and Ireland Neuroendocrine  
Tumour Society

# UKINETS Bitesize Guidance

## Goblet Cell Carcinoma

### PAGE 3 - REFERENCES

1. R. P. Warner and T. M. O'Dorisio, "Radiolabeled peptides in diagnosis and tumor imaging: clinical overview," *Seminars in Nuclear Medicine*, vol. 32, no. 2, pp. 79–83, 2002.
2. Tang LH, Shia J, Soslow RA, et al. Pathologic classification and clinical behaviour of the spectrum of goblet cell carcinoid tumours of the appendix. *Am J Surg pathol.* 2008;32(10):1429-43
3. Olsen IH, Holt N, Langer SW, et al. Goblet Cell Carcinoids: Characteristics of a Danish Cohort of 83 Patients. *PLOS ONE* | DOI:10.1371/journal.pone.0117627 February 11, 2015
4. Lamarca A, Nonaka D, Lopez Escola C, et al. Appendiceal Goblet Cell Carcinoids: Management Considerations from a Reference Peritoneal Tumour Service Centre and ENETS Centre of Excellence. *Neuroendocrinology* 2016; 103: 500-517
5. McConnell YJ, Lloyd MA, Gui X, et al. Cytoreductive Surgery with Hyperthermic Intraperitoneal Chemotherapy: An Emerging Treatment Option for Advanced Goblet Cell Tumors of the Appendix. *Annals Surgical Oncology* 2014; 21: 1975-1982
6. Rossi RE, Luong T, Caplin ME, et al: Goblet cell appendiceal tumors e Management dilemmas and long-term outcomes. *Surgical Oncology* 2015; 21: 47-53
7. Pape U-F, Perren A, Niederle B, et al. ENETS Consensus Guideline for the Management of Patients with Neuroendocrine Neoplasms from the Jejunum-ileum and the Appendix including goblet Cell carcinomas. *Neuroendocrinology* 2012;95:135-56
8. Pham TH, Wolff B, Abraham SC, Drelichman E. Surgical and chemotherapy treatment outcomes of goblet cell carcinoid: a tertiary cancer center experience. *Ann Surg Oncol.* 2006;13(3):370-6
9. Modlin IM, Lye KD, Kidd M. A five-decade analysis of 13,715 carcinoid tumours. *Cancer.* 2003;97:934-959R.

V.1 13/10/2016



UK and Ireland Neuroendocrine  
Tumour Society