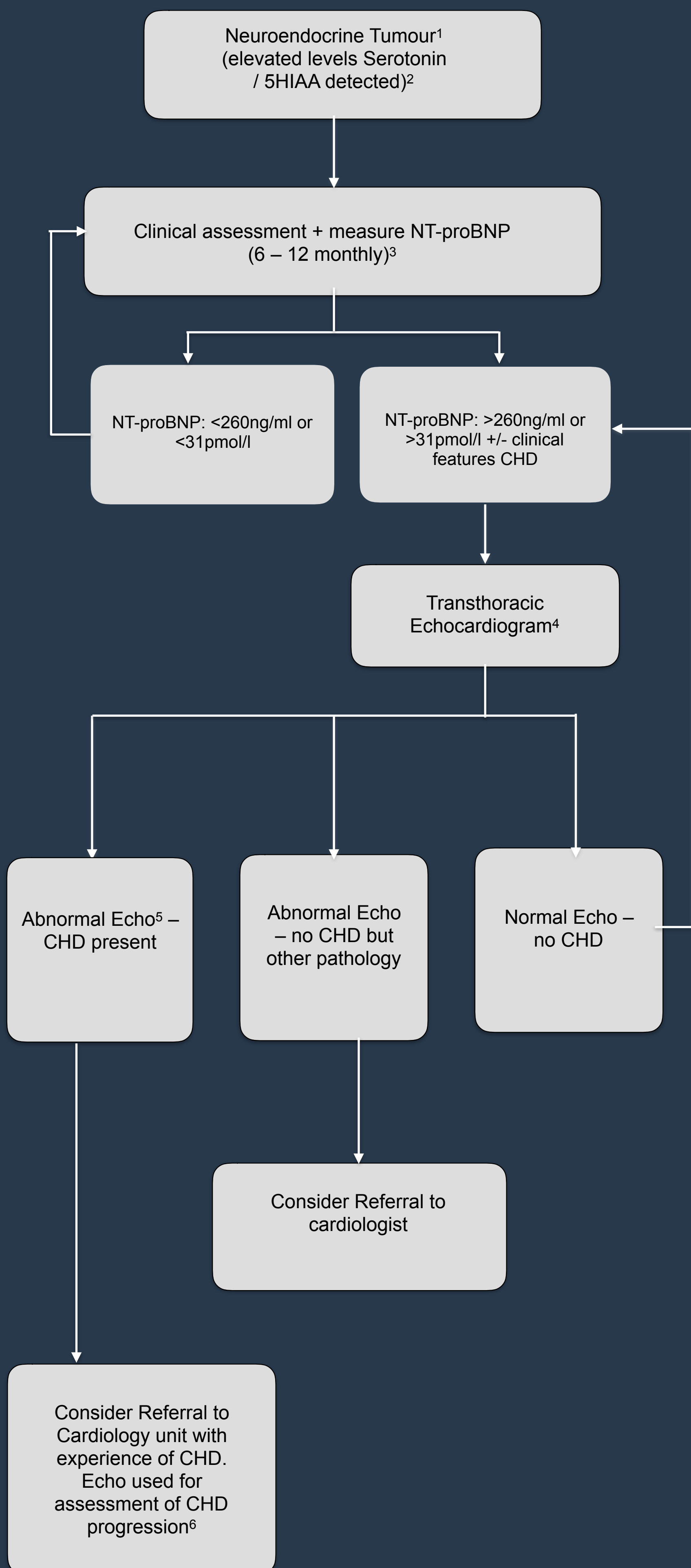


UKINETS bitesize guidance

Carcinoid Heart Disease

PAGE 1 - MANAGEMENT ALGORITHM



UKINETS bitesize guidance

Carcinoid Heart Disease

PAGE 2 - NOTES & REFERENCES

Majority of neuroendocrine cancers causing CHD will have metastases. However, primary ovarian and testicular NET can cause CHD without distant spread.

Whole blood serotonin; urinary/plasma/serum 5HIAA.

No definitive evidence of clinical significance in frequency of assessment.

Transthoracic Echocardiography is preferred diagnostic modality as widely available and well validated. Other echocardiography techniques, such as 3D, colour flow or spectral doppler, may give additional information on pulmonary valve status.. Contrast studies may help in detecting patent Foramen Ovale.

Other, rare, cardiac manifestations of neuroendocrine cancer such as cardiac or pericardial metastases may also be detected. These should be managed through the specialist neuroendocrine multidisciplinary team including cardiology and cardiac surgery.

Severity of carcinoid heart disease can change over short periods of time (< 6 months). Frequency of echocardiography surveillance of CHD is suggested 6 monthly for mild CHD and 3 – 6 monthly in moderate/severe CHD.

References

1. Diagnosing and Managing Carcinoid Heart Disease in Patients With Neuroendocrine Tumors: An Expert Statement
Davar J; Connolly H; Caplin M et al. J Am Coll Cardiol. 2017; 69: 1288-304
2. Serial surveillance of carcinoid heart disease: Factors associated with echocardiographic progression and mortality. Dobson R, Burgess MI, Valle JW et al. Br J Cancer 2014; 111:1703-9
3. Risk factors for the development and progression of carcinoid heart disease. Bhattacharyya S, Toumpanakis C, Chilkunda D. et al. Am J Cardiol 2011; 107:1221-6
4. The association of a panel of biomarkers and the presence and severity of carcinoid heart disease: a cross sectional study. Dobson R, Burgess MI, Banks M et al. PLoS One 2013;8:e73679
5. Usefulness of N-terminal pro-brain natriuretic peptide as a biomarker of the presence of carcinoid heart disease. Bhattacharyya S, Toumpanakis C, Caplin ME, et al. Am J Cardiol 2008;102:938-42
6. The optimal use of cardiac imaging in the quantification of carcinoid heart disease. Dobson R, Cuthbertson DJ, Burgess MI et al. Endocr Relat Cancer 2013;20:R247-55



UK and Ireland Neuroendocrine
Tumour Society